This is a digital copy of a book that was preserved for generations on library shelves before it was carefully scanned by Google as part of a project to make the world's books discoverable online.

It has survived long enough for the copyright to expire and the book to enter the public domain. A public domain book is one that was never subject to copyright or whose legal copyright term has expired. Whether a book is in the public domain may vary country to country. Public domain books are our gateways to the past, representing a wealth of history, culture and knowledge that's often difficult to discover.

Marks, notations and other marginalia present in the original volume will appear in this file - a reminder of this book's long journey from the publisher to a library and finally to you.

Usage guidelines

Google is proud to partner with libraries to digitize public domain materials and make them widely accessible. Public domain books belong to the public and we are merely their custodians. Nevertheless, this work is expensive, so in order to keep providing this resource, we have taken steps to prevent abuse by commercial parties, including placing technical restrictions on automated querying.

We also ask that you:

+ *Make non-commercial use of the files* We designed Google Book Search for use by individuals, and we request that you use these files for personal, non-commercial purposes.

+ *Refrain from automated querying* Do not send automated queries of any sort to Google's system: If you are conducting research on machine translation, optical character recognition or other areas where access to a large amount of text is helpful, please contact us. We encourage the use of public domain materials for these purposes and may be able to help.

+ *Maintain attribution* The Google "watermark" you see on each file is essential for informing people about this project and helping them find additional materials through Google Book Search. Please do not remove it.

+ *Keep it legal* Whatever your use, remember that you are responsible for ensuring that what you are doing is legal. Do not assume that just because we believe a book is in the public domain for users in the United States, that the work is also in the public domain for users in other countries. Whether a book is still in copyright varies from country to country, and we can't offer guidance on whether any specific use of any specific book is allowed. Please do not assume that a book's appearance in Google Book Search means it can be used in any manner anywhere in the world. Copyright infringement liability can be quite severe.

About Google Book Search

Google's mission is to organize the world's information and to make it universally accessible and useful. Google Book Search helps readers discover the world's books while helping authors and publishers reach new audiences. You can search through the full text of this book on the web at `http://books.google.com/`

THE TREATMENT OF CAVERNOUS AND PLEXIFORM ANGIOMATA BY THE INJECTION OF BOILING WATER WYETH METHOD

REDER

LANE MEDICAL LIBRARY STANFORD
2 45 01173 7998

6796



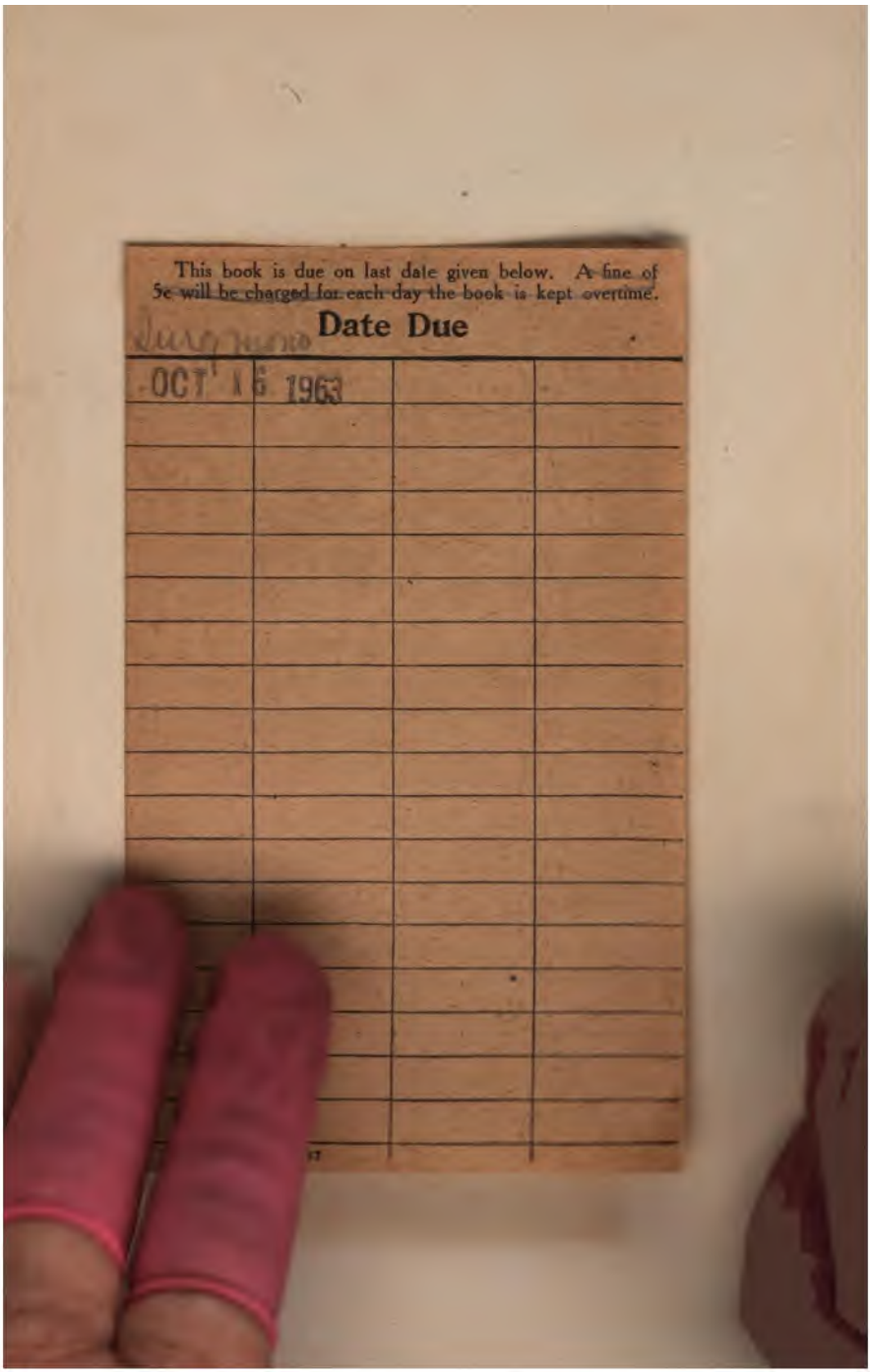
This book is due on last date given below. A fine of 5c will be charged for each day the book is kept overtime.
Date Due
OCT 16 1963

THE TREATMENT OF CAVERNOUS AND PLEXIFORM ANGIOMATA BY THE INJECTION OF BOILING WATER (WYETH METHOD)

114511

APR 1945

PLATE 1.

A typical cavernous angioma of the left cheek and upper lip.

THE TREATMENT OF CAVERNOUS AND PLEXIFORM ANGIOMATA BY THE INJECTION OF BOILING WATER (WYETH METHOD)

BY

FRANCIS REDER, M.D., F.A.C.S.,

VISITING SURGEON TO CITY HOSPITAL; CONSULTING SURGEON TO ST. JOHN'S HOSPITAL AND MISSOURI BAPTIST SANITARIUM, ST. LOUIS.

ILLUSTRATED

ST. LOUIS
C. V. MOSBY COMPANY
1918

COPYRIGHT, 1918, BY C. V. MOSBY COMPANY

Press of
C. V. Mosby Company
St. Louis

TO MY WIFE
WHO HAS SHARED WITH ME
THE "MIDNIGHT OIL"

PREFACE

Perhaps no apology is necessary for the appearance of this monograph in brochure form.

An excuse, however, may be offered on the grounds that a liberal supply of reprints has been exhausted, and though the original article appeared in *Surgery, Gynecology and Obstetrics* nearly three years ago, requests for reprints are still being received. It is the best attestation whereby the value of the procedure embodied in this brochure is to be judged. Furthermore, it conveys the conviction that physicians are alive to appreciate what appears in medical journals of high standard. A subject of special interest will usually engender the wish for a reprint. For this there is one good reason; viz., that a reprint is filed away and becomes readily accessible in case the physician wishes to refresh his mind on a particular subject, whereas the journal in which the desired article appeared is usually displaced and frequently can not be found among the mass of medical literature when it is most needed.

Dr. Stuart McQuire, of Richmond, Va., about two years ago, embodied a number of his reprints in one volume. It made a handy book. The idea impressed me as a splendid one. There have been occasions when it was my desire to obtain his

opinion on some special subjects and it was a relief to be able to do so without loss of time.

In presenting in brochure form my monograph on the treatment of vascular tumors by the injection of boiling water it is the hope that it may perhaps be of a similar service to the busy practitioner.

To the thoughtful physician this subject possesses points of interest in which advantages can readily be recognized. Would a physician remove a vascular tumor from a baby's face, especially if that baby be a girl, with the scalpel, when another measure will completely obliterate the tumor without any scar or disfigurement? If so, an excision under such circumstances would be an unjustifiable procedure. What excuse can the physician offer for the cicatrix that has been left in place of this tumor? None, except that he was not familiar with, or did not know of the existence of any other method whereby this could have been accomplished with a happier result.

When Dr. John A. Wyeth advocated the injection of boiling water into these tumors as a curative agent, I doubt very much if he was aware of the greatness of his beneficent advice. Many a mother has remembered him in her prayers for the good that has come to her child through his method. When some fifteen years ago Dr. Wyeth presented his idea of injecting vascular tumors with water at a high temperature at the meeting

of the American Medical Association, Dr. William J. Mayo, in the course of his discussion, stated that it was his belief that the procedure was one of the advances in the treatment of tumors of the blood vessels.

The farsightedness of this remark by this eminent surgeon has been fully realized. Nothing can be more convincing than to see a vascular tumor, the size of a pigeon's egg, disappear about five weeks after one or two injections of boiling water, and leave the structures in a state bordering on the normal.

For my successes I am deeply indebted to Dr. Wyeth. It has been my good fortune to enjoy a number of visits with this master surgeon where I could hear from him in a most interesting manner his views and ideas on the treatment of these vascular tumors. During one of my visits when the doctor enlightened me with most valuable suggestions relative to this procedure, I asked him if he would be kind enough to write a few lines about the treatment of vascular tumors by the injection of water at a high temperature in the way of an introduction, should I decide to present the subject in brochure form. To this request he gave me an affirmative reply, for which I am very grateful.

FRANCIS REDER.

ST. LOUIS, MO.

ILLUSTRATIONS

PLATE PAGE

I. Cavernous angioma of left cheek and upper lip Frontispiece
II. Plexiform angioma . . . . . Facing 28

FIG.

1. Angioma of right cheek complicated by nevus 20
2. Angioma of lower lip 21
3. Angioma of lower lip in left corner of mouth 22
4. Angioma of tip of nose and underneath upper lip . . 23
5. Angioma of left upper eyelid 24
6. Angioma of left frontoparietal region 25
7. Angioma of right middle finger near knuckle 26
8. Angioma of left gluteal region 27
9. Angioma of tongue 34
10. Cavernous angioma of right cheek of congenital nevoid origin 37
11. Front view of case shown in Fig. 10 38
12. Showing result of Wyeth treatment and paquelinization . 39
13. Front view of case shown in Fig. 12 40
14. All-glass syringe 42
15. Jacketed syringe and cork-protected needle 44
16. Operating room arrangement 46
17. Injection of boiling water 47
18. Plexiform angioma 53
19. Showing the result of Wyeth treatment in case shown in Fig. 18 54
20. Angioma of left upper eyelid 56
21. Showing result of Wyeth treatment in case shown in Fig. 20, front view 57
22. Showing result of Wyeth treatment in case shown in Fig. 20, lateral view 58
23. Cirsoid aneurysm 60
24. Showing result of Wyeth treatment in case shown in Fig. 23 61
25. Cavernous angioma of left cheek and upper lip 65
26. Showing result of Wyeth treatment in case shown in Fig. 25 67

INTRODUCTION

By Dr. John A. Wyeth

While limited to a comparatively narrow field, the value of water at a high temperature as a therapeutic agent has been fully demonstrated.

It is more than seventeen years since I first employed this method to coagulate subdermally the blood and lymph for the arrest of the circulation in arterial, venous, capillary, and lymphatic angiomata. A certain proportion of these neoplasms are at times inoperable, either by the ligature or by excision, on account of noncontrollable hemorrhage; and among the most gratifying experiences of my career have been the cure of a very considerable number of cases, which, without this method of treatment, must have been hopelessly abandoned to untimely death, or to lifelong disfigurement.

It is essentially applicable to the arrest and cure by ultimate absorption of that form of arterial angioma (cirsoid aneurysm) which most frequently affects the arteries of the scalp, and to the large, venous angiomata with rich anastomoses, which, while in the majority of instances are found above the level of the clavicles, may be met with in any part of the body. So far, all of these cases have been successfully treated, and, to my surprise, without disaster, even from embolism.

I am confident the author of this monograph will deal with the technic in detail. The fact will ever be present in the operator's mind that water, at or above, 212° F. is instantly destructive of the skin in the presence of the atmosphere. Even subdermally a too intense heat should not be used near the skin or a vessel, or a vitally important nerve.

THE TREATMENT OF CAVERNOUS AND PLEXIFORM ANGIOMATA BY THE INJECTION OF BOILING WATER (WYETH METHOD)

An angioma is a vascular tumor, nonmalignant in character. On an anatomic basis, angiomata can be classified as venous, which are rather frequently observed; then arterial, or plexiform angioma, otherwise known as a cirsoid aneurysm, the "angioma arteriale racemosum" of Virchow, a vascular neoplasm rarely observed, and, lastly, the capillary form, the so-called "port-wine stain" or "mother's mark," which is quite common.

The theory that these neoplasms are caused by a dilatation of the capillaries, the walls of which have become absorbed, resulting in the formation of spores, has been favorably received. Of the cavernous angioma, it can be said that it is a large, blood-filled nonpulsating cavity, of variable size, with a thin covering of skin, usually bluish in color.

The walls of these spaces possess an endothelial lining similar to that of veins. Numerous tortuous vessels supply the blood which fills these cavities and circulates with varying degrees of rapidity. The arteries open directly into the cavities.

The connective tissue enmeshing the vessels of an angioma is sometimes scanty and sometimes plentiful, thus causing irregularities about the vascular tumor that often give it a lobulated appearance.

A venous angioma may be diffuse, or may form a distinctly circumscribed tumor. A circumscribed cavernous angioma possesses its distinct efferent artery and afferent veins and does not communicate with the neighboring capillaries; i. e., there exists no anastomosis with the capillaries in the surrounding tissue. The angioma shows a circulation wholly within itself, there being only a connection with the neighboring arteries and veins.

Their growth is slow. They increase, however, progressively in size with the growth of the patient; viz., a baby which at three months shows an angioma upon its lip that has the appearance of a fleabite, will exhibit the same lesion the size of a hazelnut nine months later.

These vascular neoplasms are congenital in their origin. They are benignant in character and although their histologic formation closely resembles certain types of malignancy, yet clinically angiomata are considered nonmalignant.

One of the principal characteristics of a hemangioma is that the entire tumor can be caused to disappear upon pressure, with a prompt return to its original size as soon as the pressure is removed.

Another characteristic is the prompt response in reflecting the temperament of its possessor, excitable influences causing the tumor to swell, become tense, and more deeply discolored. This is accomplished through elastic fibers, closely resembling the normal erectile tissues of the body, which are contained in the connective tissue stroma.

From statistics it must be inferred that the face is the favorable locality for an angioma, two-thirds of these growths being located there.

The brow and the cheeks seem to be selective regions. Next in frequency come the lips, the nose, the ears, and the eyelids. Strange as it may appear, the feminine sex is more prone to this affection than the male, two-thirds of all cases occurring in females.

Cavernous angiomata may occur in the orbit, muscle, liver, spleen, kidneys, and the alimentary tract. These vascular tumors have also been found in bone, the "myelogenous angioma" of Virchow, an extremely rare condition. Its resemblance to osteosarcoma is very great, making an *intra vitam* diagnosis almost impossible.

Inasmuch as there is no pain in connection with a cavernous angioma, except when the tumor is so located as to cause pressure upon a nerve, the discomfort experienced must be ascribed to its size and, of course, its location. For instance, a vascular tumor situated upon the upper eyelid can become very annoying on account of visual inter-

Fig. 1.—Baby G., age eighteen months. Angioma of right cheek, complicated with a nevus. Four injections obliterated the angioma. First injection, September 10, 1913, 3 ounces; second injection, October 12, 1913, 3 ounces; third injection, December 6, 1913, 2 ounces; fourth injection, February 18, 1914, 2 ounces. The tumor had entirely disappeared by June 1, 1914. The nevus was destroyed with two applications of the Paquelin cautery.

Fig. 2.—Baby M., age seven months. Angioma of lower lip. One injection of boiling water obliterated the angioma. The angioma was injected with 1.5 ounces January 5, 1914. There was complete disappearance of the tumor by April 1, 1914.

Fig. 3.—Baby C., age two years. Angioma of lower lip in left corner of mouth. When baby laughed this tumor would roll out of the corner of the mouth and appear as large as a California grape, dark purple in color. Three injections obliterated the tumor. First injection, April 6, 1914, 0.5 ounce. Second injection, June 3, 1914, 0.5 ounce. Third injection, October 11, 1914, 0.5 ounce.

Fig. 4.—Peter E., age nineteen years. Angioma on tip of nose and underneath upper lip. Two injections required for tumor underneath the upper lip, and three injections for angioma on tip of nose. Owing to the cartilaginous structure of the tip of the nose, much difficulty was experienced in making these injections. First injection, June 2, 1911; nose, 0.5 ounce, lip, 1 ounce. Second injection, July 8, 1911; nose, 0.5 ounce, lip, 1 ounce. Third injection, September 2, 1911; nose, 0.5 ounce. Complete disappearance by October 1, 1911.

Fig. 5.—Baby E., age three years. Angioma involving left upper eyelid. This tumor grew rapidly during the last four months and interfered with vision. Two injections obliterated angioma. First injection, January 3, 1912, 2 ounces. Second injection, March 1, 1912, 1 ounce. Disappearance of tumor by July 1, 1912.

Fig. 6.—Baby K., age eighteen months. Angioma in left frontoparietal region. Two injections obliterated the angioma. First injection, May 2, 1914, about 2.5 ounces. Second injection, May 28, 1914, about 1.5 ounces. Disappearance of the tumor by August 1, 1914.

Fig. 7.—John F., are thirty-two years. Angioma of right middle finger near knuckle. One injection of 2 ounces caused the tumor to disappear in six weeks.

Fig. 8.—Frank L., age forty years. Angioma of left gluteal region. Five injections required to obliterate this tumor. First injection, February 4, 1910, about 5 ounces. Second injection, March 6, 1910, about 5 ounces. Third injection, May 2, 1910, about 3 ounces. Fourth injection, June 18, 1910, about 3 ounces. Fifth injection, August 2, 1910, about 2 ounces. Complete disappearance of tumor by November 1, 1910.

ference. Again, an angioma of the cheek may involve the buccal tissue to such an extent as to make mastication difficult and even dangerous. This was exemplified in one of my cases in which the patient accidentally bit the inner side of her cheek, causing an alarming hemorrhage.

Now, let us consider briefly the plexiform angioma. This is usually a distinctly outlined tumor occurring in definite arterial regions. According to Fischer, 12 per cent are of traumatic origin, the remaining 88 per cent being derived from simple congenital angioma.

The tumor is composed of arteries and veins, the tortuous vessels giving this tumor mass a most characteristic appearance.

A favored site is upon the forehead, scalp, and face. It is not infrequent, however, to find the hand, fingers, and forearm affected.

In its clinical characteristics a plexiform angioma differs markedly from the cavernous type. The former usually forms a flattened tumor, gradually spreading into the surrounding tissues. The skin covering the tumor is very thin, usually more of a reddish than a bluish color, and is locally adherent. Pressure upon the mass will not cause it to be completely evacuated, as is the case in a cavernous angioma. This must be attributed to the large number of anastomoses.

Another characteristic phenomenon found in the plexiform angioma and not present in the cav-

PLATE II.

A typical cirsoid aneurysm (plexiform angioma) of the forehead, a favorite site for these vascular tumors.

ernous variety is the well-marked pulsation and bruit. For instance, the hand flatly applied to a plexiform angioma will distinctly perceive the pulsation and bruit in the tumor. Such an angioma located on the scalp or forehead will often cause a partial destruction of the underlying bone by attrition. This defect can be readily discovered by making gentle, but firm pressure upon the thinned-out skin of the tumor, at the same time sweeping the finger over the affected area.

A plexiform angioma is not free from clinical symptoms; it usually causes dizziness, vertigo, and a dull pain in the head. Such disturbances are not associated with a cavernous angioma.

The capillary form of angioma has very little of clinical significance, and exclusive of the unsightly appearance, causes no discomfort. It is not often that the possessor of a port-wine stain seeks advice as to the possibility of having it removed. Even so, should the angioma involve a large area, which they not infrequently do, nothing of an encouraging nature as to its total or even partial removal could be promised.

An interesting fact in connection with capillary angioma is that their distribution often corresponds to the area of distribution of the three branches of the fifth cranial nerve; viz., angioma of the frontal germinal area, and angioma of the superior and inferior maxillary areas. Bärensprung was the first to call attention to this. Cush-

ing and others later confirmed his observations. Simon entertained a theory that nutritive disturbances in the region of the trigeminus were causal in producing such a condition.*

Virchow advanced a theory that angiomata find their origin in the embryonic relations when slight irritative conditions about the margins and the circumference of the fetal clefts, which are always copiously supplied with blood vessels, may cause an abnormal development about these parts, with the possibility of a nevus formation. Such a condition may remain latent for a time and later manifest itself as a cavernous angioma. Virchow has applied to them the name of "angioma fissuraux."

According to Ribbert, the genesis of angiomata rests with two questions: Is the tumor a simple dilatation of the vessels in a circumscribed area? or, is the tumor the result of a new growth? To this may be added Stangl's argument as to whether or not these vascular tumors are of epithelial or connective tissue extraction. Ribbert advocates the view that they are the result of a new growth. From the exhaustive researches that this interesting vascular lesion has been subjected to, the inference must be made that the genesis of angiomata is not clearly understood.

*Larry in his interesting exposition of this lesion adheres to a theory that angiomata are congenital vascular productions caused by modifications occurring during embryonal development.

A cavernous or plexiform angioma, especially of large size, is one of the most difficult lesions with which the surgeon has to contend. In fact, some of these lesions are looked upon as inoperable and have been abandoned to an ever-increasing deformity and discomfort.

The most radical intervention for the "cure" of an angioma is excision. However, before having recourse to this measure, it is well to consider several salient points. One, a point of much import, is the size and location of the angioma, and the risk to life from hemorrhage. Another point, and one that commands recognition, especially when the angioma is located on the face, is the liability to deformity from mutilation and cicatrization.

These two points can be fused into one consideration for the surgeon who attempts to cure an angioma by excision; viz., that this radical measure is only permissible when the vascular tumor is of limited extent, well-circumscribed, and situated in parts which can be sacrificed without the danger of great hemorrhage or the loss of important structures.

In an angioma of the face, the effect of a mutilating or disfiguring operation must be seriously considered, especially in the female sex.

That many of these tumors are inoperable; i. e., not amenable to extirpation, has been demon-

strated repeatedly by an attempted operative measure which had to be abandoned.

Other surgical measures, such as peripheral ligation, ligature of the afferent arteries, and tissue strangulation by the buried ligature, have been considered when a surgical extirpation seemed too hazardous. However, the results have at best been only palliative and disappointing.

The severity of the surgical intervention in dealing with an angioma caused other methods to be promulgated. Efforts were made to destroy the growth with all its constituent elements by the interstitial action of irritating caustics or other agents applied externally or introduced into the afflicted tissues. Some of these methods have been used by me, but have proved disappointing.

For instance, the injection of alcohol (Schwalbe) and ferric sesquichloride are very prone to cause suppuration, and are not to be recommended. Injection of hydrogen peroxide (Mosetig-Moorhof) is a dangerous agent to use. Its introduction may be followed by a fatal gas embolism in the lungs. Payr's method, consisting of the introduction into the tumor of darts or rods of magnesium, a procedure that does not involve the danger of thrombosis or embolism, is not familiar to me, neither have I had any experience with radium.

The injection of water at the boiling point as recommended by Dr. John A. Wyeth has given me the most satisfactory results. The method must

be looked upon as one of the advances in the treatment of vascular tumors. Of 104 cases subjected to this method, I have had no failures to record. The results were certain, and the procedure was free from accident. There are two cases, however, of which I wish to briefly speak.

In the first case, a child of sixteen months, with an angioma on the lower lip to the left of the midline, in size as large as a filbert, had received two injections in the course of six weeks. The tumor was reduced to slightly less than half its size. It was then quite hard and its color, which before the injection, was purple, was that of the normal lip.

The mother became dissatisfied that the tumor had not entirely disappeared. At the advice of her friends, she saw a physician who removed it by excision. The removal was a success, and were it not for the scar on the lip the result would have been ideal.

I was informed by the physician that the removal was attended with but little bleeding. This must be explained on the assumption that the blood in the tumor, coagulated by the boiling water, had become well organized. The mouths of the vessels opening into the vascular tumor had been well sealed. It was noticed during the second injection that the boiling water did not enter the vascular growth so easily as during the first. More piston pressure was necessary, and the dif-

Fig. 9. [illegible] Angioma of tongue. Tumor was size of [illegible] and was located midway on the right marginal side. A little less than an ounce of boiling water was injected. The resultant edema spread to the epiglottis and so embarrassed breathing that six hours after the injection it became advisable to perform laryngotomy. Thirty six hours later the edema had subsided and breathing became normal. The tube was then removed. Patient made a prompt recovery. Angioma had entirely disappeared eight weeks later.

This distressing condition could have been avoided if a smaller dosage of boiling water had been injected and repeated to meet conditions later as they presented themselves. This was demonstrated in two subsequent cases when an extensive edema was anticipated by resorting to small quantities of boiling water and repeating the injection.

ficulty was plainly apparent. This was noticeable in every angioma of the lip that required subsequent boiling-water injection.

The structure of the lip is peculiar in its make-up, and it is advisable to use extra precautions while introducing boiling water into these structures. It is far better to subject the tumor to a subsequent injection, rather than have an overdistention during the first injection that may be the cause of a slough. The greatest success in a lip angioma, however, can be obtained by introducing the proper quantity of boiling water at the first injection. Otherwise, conditions may arise, as those just cited, which may invite excision.

It is gratifying, however, to know that an angioma of the lip which had not been entirely obliterated by the injection of boiling water can be excised with very little loss of blood.

The other case was that of a young man who had an angioma midway on the right margin of his tongue. The growth was as large as a pecan nut and deep purple. Not quite an ounce of boiling water was introduced into it. Within six hours the edema had involved the epiglottis to such an extent that breathing was seriously embarrassed. It was necessary to perform a laryngotomy. In thirty-six hours the edema had subsided and breathing again became normal. The angioma disappeared entirely in eight weeks.

In this case too much boiling water had been

injected at once. It would have been safer to have given a smaller amount, repeating the injection in three or four weeks, if necessary.

The question, whether or not a cavernous or a plexiform angioma is a lesion that endangers life, must be answered in a guarded manner. These vascular tumors possess an element of danger in proportion to their size and location. When there is noninterference, their growth may eventually produce a secondary lesion by spreading indefinitely, which may cause death. When there is operative intervention, that is, excision, the great danger is hemorrhage.

The injection of boiling water is not entirely free from danger. However, of all the procedures it is unquestionably the safest. The danger of an embolism must be reckoned with, and in all injections peripheral compression while the boiling water is being introduced into the tumor must be made.

There is always a possibility that boiling water injected into a plexiform (cirsoid aneurysm), located upon the head, might be productive of a meningeal trouble. Furthermore, it may be readily seen how a slough can result from boiling water when injected into a cavity filled with blood. It is not a simple matter to judge a boiling water injection.

Before speaking of the technic of the boiling-water injection, I wish to say something about a

Fig. 10.—Neoma K., age five years. Cavernous angioma of face of congenital nevoid origin. Two injections of 2 ounces and 1½ ounces respectively covering a period of six weeks completely obliterated the angioma. The nevus was destroyed with the pointed Paquelin cautery. Three applications at intervals of four weeks were necessary to efface this obstinate vascular growth.

Fig. 11.—Neoma K., age five years. Front view of case shown in Fig. 10.

Fig. 12.—Neoma K., age five years. The slight shading about the malar region depicts the site of the nevus and the result of paquelinization.

Fig. 13.—Neoma K., age five years. Result after treatment of case shown in Figs. 10, 11, and 12.

type of nevus which is elevated above the skin, and has been of interest to me. It is not infrequent that a nevus complicates an angioma. The treatment of a nevus has proved more or less unsatisfactory to me, no matter what method I employed. The Paquelin cautery with round point has given the best results, yet that was not satisfactory because recurrences were numerous, requiring frequent applications of the cautery. This procedure usually resulted in a well-defined scar, which was very undesirable.

By using the boiling-water injection in conjunction with the cautery, I found that usually with one application of the cautery a satisfactory obliteration of the nevus could be accomplished. This is to be explained on the ground that the nevus is fed by deeper lying vessels, even in the absence of an angioma. The injection of boiling water introduced underneath the skin in the connective tissue in the immediate vicinity of the nevus will obliterate these vessels, thus depriving the nevus of further nourishment. The cautery, with the aid of this starvation, will usually prove successful with one application.

In making the injection of boiling water into an angioma certain conveniences will expedite this measure. A suitable syringe is essential. I have found that an all-glass syringe with a good shoulder, a large ring on the piston, and an asbestos

Fig. 14.—All-glass syringe, small size, for injecting boiling water into an angioma. Note the asbestos plunger, the large ring at the end of the piston, the shoulder of the barrel, and the point of the barrel which is ground to receive the "slip" needle. A syringe with a capacity of one or two ounces is the preferable syringe for boiling water injections.

plunger, has answered the purpose better than any of the many I have tried.

A syringe with an all-glass plunger has its drawbacks, as the steam generated within the barrel will find its way between it and the glass plunger, thus inhibiting the free and easy movement of the piston, so essential to this procedure.

The slip needle (small caliber, No. 20) is the preferable one. With it no time is being lost in the transference of the boiling water. It should always be borne in mind that the water must be injected at a boiling temperature and time is an important factor. It can be stated that those cases of angiomata subjected to the boiling-water treatment which did not respond properly, did not receive the "water" hot enough.

To protect the hands, at the same time making it possible to handle the boiling water, a pair of easy-fitting chamoisette gloves of good thickness have served me well. That portion of the glove intended for the little finger is cut off, so that the degree of heat in the tissues can be judged by occasional contact with the exposed end of the finger.

Another protection for the hands of the operator, while transferring the boiling water, and one which has been found very valuable because it does not require the wearing of gloves, was contrived by jacketing the barrel of the syringe with a heavy piece of white rubber tubing. The tubing

Fig. 15.—Showing how the barrel of the syringe is jacketed with a piece of white rubber tubing. The "window" in the jacket is placed so that, should the boiling water be drawn beyond the edge of the tube, it can be seen and its expulsion controlled. Note the "shoulder" of the needle imbedded in a cork, so that the transmitted heat from the boiling water will not burn the unprotected finger steadying the needle.

does not cover the barrel to its full length, as this is not necessary with the syringe that is generally used. It permits the exposure of the lower half, and inasmuch as the syringe is never drawn full of boiling water when an injection is made, it is an advantage in being able to watch the amount of water that is being forced out.

To furthermore facilitate observation in case the boiling water is drawn beyond the edge of the rubber jacket, a "window" is cut into the lower half of the tube.

To protect the fingers of the hand engaged in steadying the needle from the heat that will be transmitted to the needle, a cork placed about the "shoulder" of the needle has been found very efficacious.

This method of protection has the advantage of having the hands unincumbered with gloves.

The arrangement in the operating room should be such that the surgeon stands between the vessel containing the boiling water (the water being kept constantly at the boiling point over a flame), and the patient, at a distance that will not necessitate a step on the part of the surgeon for the transference of the boiling water into the tumor.

The parts not involved should be protected with moist cloths, lest a scalding of these tissues result from the hot water in the syringe being forced out at the needle junction by the generated steam.

The introduction of the needle and the force

Fig. 16.—Showing position of surgeon and patient for an injection of boiling water. Note the distance between surgeon and patient and the open vessel containing the water at boiling point over a flame. The movement on the part of the surgeon in transferring the boiling water is barely a quarter of a circle. The canula is previously introduced into the region where the injection is to be made. It requires only a second to make connection with the syringe.

Fig. 17.—Showing how the boiling water is being injected into an angioma.

applied in injecting the hot water is of much importance. Inasmuch as the tissues of the new growth do not offer the resistance of normal skin, the hot water injected without great care may cause these tissues to break down. Injections made directly into the soft vascular mass are invariably followed by a necrosis.

For this reason, it is well to make the initial injections by introducing the needle through the sound skin about one-sixteenth or one-eighth inch from the edge of the angioma well into the base of the vascular tumor, thus assuring coagulation of the deeper parent vessels. This is also a wise precaution against the dangers of embolism.

If the arteries leading into the tumor can be demonstrated, it is well to enter the needle along their course and inject a sufficient amount of boiling water to cause coagulation in these vessels.

Judgment should be exercised in introducing the needle to prevent the point from resting too near the opposite wall of the tumor. To properly estimate this procedure, it is well to first introduce the needle without the syringe, pushing it through the mass till it can be felt on the opposite side, then withdraw to the extent of half an inch. This will give a reasonable assurance that the boiling water can be injected into the tumor without the likelihood of getting a slough. When the skin begins to show signs of becoming blanched and turns grayish in color, the injection into that area is to

be discontinued. Hyperdistention must be carefully guarded against. The amount of hot water necessary to cause this bleaching rests wholly with the amount of tissue under treatment. After coagulation of this particular area has been satisfactorily accomplished, the point of the needle is made to penetrate into another area of the tumor and the hot water injected.

In this manner the needle is introduced into the tumor in different places, and at various angles, till the whole mass gives evidence of coagulation.

The quantity of hot water which may be injected at one sitting can amount to three or four ounces in a tumor the size of a hen's egg, the time consumed in making the injection being about three minutes.

However, if the new growth is of unusual size, it would be advisable to inject only a portion of the tumor at one time, making a subsequent injection two or three weeks later.

It may be stated here that safeguarding not only becomes an imperative measure when tumors of an unusual size are to be injected. Even tumors of small size when located upon the tip of the nose, upon the eyelid, or upon the tongue, must be approached with great caution. A boiling water injection of an angioma involving the tip of the nose, if injudiciously given, might cause a necrosis of the nasal cartilages, a very distressing accident, should it occur. An injection into an angi-

oma upon the upper eyelid must be administered most cautiously on account of the damage which might be inflicted upon the eye; while an angioma of the tongue, when injected with too copiously a dose of boiling water, may cause the edema to involve the epiglottis and seriously embarrass respiration. It was my misfortune to meet with such a mishap (see case history).

Boiling water injections into an angioma situated in these regions must be given with good judgment plus great care.

It is interesting to observe the characteristics presented by an angioma subjected to the hot water treatment. The independence of the blood spaces from the blood vessels of the surrounding tissue can be demonstrated by the fact that the neighboring tissue is not affected; i. e., none of the hot water finds its way into the adjacent structures while the injection is being made. However, shortly after the injection an edema of the immediate parts begins to manifest itself. This edema may be very extensive, according to the amount of hot water injected. Frequently, when the lesion is on the face, the swelling may become so extensive as to close the eyes.

Although the condition looks alarming, there is little ground for actual fear, except when an injection is made for an angioma on the tongue. The patient suffers no pain, the condition is an

afebrile one, and the edema usually subsides within the first week.

It is a wise precaution to apply ice or cold compresses to the tumor and surrounding tissues immediately after the injection for the first four to six hours, thereby lessening the severity of the edema.

At the end of the first week the tumor, but slightly diminished, has almost fully lost its pathologic color and the tissues are beginning to assume a normal appearance.

To the touch, the mass is hard. If it remains hard, the metamorphic process is active and no further injection will be necessary. Should the tumor, however, begin to show evidence of softening with visible formation of a new blood supply, an immediate injection is indicated.*

The course of an angioma successfully injected is one of gradual diminution, the greatest progress being made from the second to the third week. A tumor the size of a hen's egg will usually require six to eight weeks for its disappearance. If the injection has been a fortunate one, i. e., free from accident, such as cicatrization following sloughing, the site that once harbored the angioma will appear healthy and quite normal.

It is advisable that a general anesthetic be ad-

*A successful obliteration can only be accomplished by granular metamorphosis, made possible by the coagulation of the blood and albuminoids; i. e., the effect of the boiling water in the tissues is to speedily bring about vascular blockade, lymph infiltration, and cell retrograde, followed by restoration to healthy conditions.

ministered. The assurance of greater accuracy in administering the injection is thereby given. Sometimes, however, a general anesthetic may carry with it elements of danger, as has been the case in a cirsoid aneurysm, when the anesthetic had to be discontinued for fear of bursting the tumor. I have repeatedly given the injection without an anesthetic and was astonished that the pain was not more severe.

A Case of Plexiform Angioma (Cirsoid Aneurysm)

(See Figs. 18 and 19.)

J. W., age forty-three, a carpenter, struck the frontal portion of his head against a joist six years ago. Two years later he noticed a swelling in his forehead which gradually became larger, spreading beyond the hair margin onto the scalp. During the last six months, he suffered much with dizziness and noises in his head.

Examination revealed a tumor mass involving the frontal region back to the coronal suture. Laterally the swelling extended to the temporal ridge. The tumor mass was evenly distributed. A hand placed flat upon the forehead would give a good idea of its size.

The tumor was bluish in color and the undulations of its surface gave it a convoluted appearance. All vessels leading to it were tortuous and

filled to such an extent as to make them appear abnormally large. Distinct pulsations in the vascular tumor were perceptible and a marked aneurysmal bruit and fremitus were present.

There was considerable destruction by attrition of the outer table of the skull.

Fig. 18.—J. W., age forty-three years. Plexiform angioma (cirsoid aneurysm) of forehead. Injected with five ounces of boiling water at one sitting. Seven weeks later the tumor had disappeared.

On August 10, 1917, under a general anesthetic, this tumor mass was injected with five ounces of boiling water. As soon as the water was intro-

duced into the cavity of the tumor, pulsation ceased. The doughy feeling of the mass gave evidence of thorough coagulation of the blood.

An edema began to develop immediately. In two days it had reached its height. It involved

Fig. 19.—J. W. Plexiform angioma (cirsoid aneurysm). Appearance of patient shown in Fig. 18, two months after injection.

the upper half of the face, closing both eyes. After the third day, the edema subsided rapidly, and the patient was able to leave the hospital on the fifth day.

Seven weeks later, all evidence of the cirsoid aneurysm had disappeared. There was only a slight thickening discernible at its former site and that was undoubtedly due to an infiltrated periosteum. The dizziness and noises in the head had disappeared.

A Case of Cavernous Angioma

(See Figs. 20, 21, and 22.)

Miss G., age thirty-three years. Left upper eyelid harbors an angioma as large as a hen's egg. A picture of the patient taken when two years old shows the left eye closed by a tumor mass in the upper eyelid. The sight in the left eye, though weak, is normal, the tumor, however, robbing the patient of its usefulness.

At the age of fifteen years, an operation, by a skillful surgeon, was performed. The operative measure consisted in the ligation of vessels leading to the angioma. There was a slight improvement, but not enough to open the eye.

A year later, the condition getting worse, i. e., the vascular tumor enlarging, another operation of a similar nature to the previous one was performed. No improvement.

In October, 1914, the patient went to a New York surgeon to subject herself to the radium treatment. This treatment was refused, injury to the eye being feared. An operation at St. Luke's

Fig. 20.—Miss G. A typical angioma of the left upper eyelid since babyhood. Three extensive operative measures were unsuccessful. The condition of the cicatricial tissue resulting from these operations inhibited to some extent the action of the boiling water. However, three injections covering a period of seven months brought about a most gratifying result. (See detailed history.)

Hospital was performed instead. This operation gave considerable improvement. Patient was able to slightly elevate the upper eyelid.

Fig. 21.—Miss G. Full view of case shown in Fig. 20. The result after three injections of boiling water covering a period of seven months.

This improvement lasted four months, when the blood tumor again began to show evidence of enlarging.

In July, when I saw the patient, a bluish mass, very soft to the touch and about as large as a hen's egg, appropriated the upper eyelid.

Fig. 22.—Miss G. Lateral view of case shown in Figs. 20 and 21. The result after three injections of boiling water covering a period of seven months.

There were numerous scars in the immediate vicinity of the eye, evidences of former operations. There was a very conspicuous cicatrix

along the orbital ridge, evidently the remains of an attack on the supraorbital artery.

The location of the angioma made the boiling water treatment a rather hazardous undertaking. Under extraordinary precautions, three injections were given, covering a period of seven months (the first injection was given July, 1915, the last February 1, 1916). Owing to the great amount of cicatricial tissue about the angiomatous area, the influence of the boiling water was to some extent interfered with. Nevertheless, the angioma was made to disappear. The patient is now able to open her eye to two-thirds normal. The color of the skin is almost normal.

The sight of the eye, which at first was very weak, is being gradually restored with the aid of a proper lens.

Case History of Mr. F. in Detail

(See Figs. 23 and 24.)

A carriage painter, never seriously sick, was referred to me by Dr. C., Quincy, Illinois.

As far back as fifteen years he had experienced attacks of dizziness. During the last two years he had been unable to follow his trade as carriage painter on account of the severity of these attacks. Has had a small swelling behind his ear as long as he could remember. Four years ago the swelling had grown to such a size that it crowded

Fig. 23.—Mr. F., age thirty-two years. Cirsoid aneurysm behind right ear extending well down on neck. This patient had been subjected to a surgical measure with almost fatal results. Two injections were sufficient to cause obliteration of the angioma. First injection, March 14, 1909, 6 ounces. Second injection, April 18, 1909, 4 ounces. Tumor mass disappeared by June 1, 1909. (See detailed history.)

Fig. 24.—Mr. F. Appearance of patient shown in Fig. 23, June 1, 1909.

his right ear forward and extended into his scalp and down upon his neck.

The condition of the tumor mass when he consulted me, March, 1909, presented these characteristics: Extending from the midparietal region near the center of ossification on the right side down to the clavicular region, the tumor occupied the entire right half of the occipital region, crowding the right ear markedly forward. The contour of the tumor was clearly defined. The mass proper was elevated to a level with the helix of the ear. That portion of the tumor involving the neck was of a bluish discoloration. Upon palpation a distinct pulsation and a bruit were readily detected.

With the application of pressure the contents of the swelling could be forced out easily. Upon releasing the pressure the tumor promptly reappeared. With touch the roughened bone margins and many irregularities of the skull underlying the tumor could be distinctly discerned. This destruction of bone was caused by attrition of the pulsating mass.

About the lower pole of the tumor were a number of cicatrices, the result of an attempted operation. The patient informed me that he almost perished from loss of blood when the operation was undertaken.

The condition of this patient was one of extreme distress. The ringing and noises in his right ear

were incessant. He was unable to be on his feet on account of vertigo and was compelled to sleep in a sitting posture.

An attempt was made to administer an anesthetic preparatory to the injection of boiling water. This, however, was found to be too hazardous a procedure, the influence upon the tumor mass being such that it appeared as though it would burst.

The injection of hot water was made without an anesthetic, and about six ounces were introduced. In making the injection, all factors of safety were considered: the scalp had been shaved and cleaned, and during the injection peripheral compression was diligently exercised.

The needle was first introduced at the lower pole in the neighborhood of the vessels that led into the tumor. As soon as there was evidence of coagulation, following the injection, the needle was withdrawn and reinserted into the tumor at a different site. The needle was introduced about one-eighth inch from the mass. In this manner the whole of the tumor base was injected. After six ounces of hot water had been introduced into the mass it ceased to pulsate. While the injections were being given, cloths wrung out in ice water were frequently applied to the mass, which had become quite hot.

The condition of the patient following the first injection, exclusive of the enormous swelling that

followed (the edema involved the right side of the face, closing the right eye, and encroached upon the neck, throat, and chest), was very encouraging. He appeared more comfortable, the ringing in his ear had ceased, and he was able to lie in bed. At the end of four weeks the growth had diminished to less than half its size. The patient could sleep well and was able to walk about without experiencing dizziness. A second injection of about four ounces of hot water was given at that time. Six weeks later the tumor mass had practically disappeared, excepting a small mass the size of a pigeon's egg at the angle of the mandible which had the appearance of an enlarged gland. An attempt was made to inject it, but the substance was found to be too resistant.

Case History of Miss S. in Detail

(See Figs. 25 and 26.)

Always in good health, with splendid physical proportions, suffered much from periods of marked depression. Since childhood had a small bluish spot on her upper lip and immediately below left eye upon malar prominence. Seven years ago the bluish spot on the lip began to enlarge. It continued to grow very gradually and was the size of a tangerine when she presented herself to me June 6, 1906.

This was the condition of her face. The right

Fig. 25.—Miss S., age twenty-four years. Angioma of left cheek and upper lip. Ligation method with loops of silk tried and failed. Five injections of boiling water and one injection of alcohol obliterated the tumor mass. First injection, June 25, 1906, 4 ounces. Second injection, August 2, 1906, 3 ounces. Third injection, August 18, 1906, 2 ounces. Fourth injection, August 30, 1906, 1 ounce. Fifth injection, September 25, 1906, I ounce. Sixth injection, October 8, 1906, 1 ounce. Alcohol was substituted for boiling water on account of fear of too great a contraction with a possible deformity about the lip. (See detailed history.)

side, excepting two-thirds of the portion of the upper lip, was normal. The left side showed a marked swelling of the cheek which pushed up the lower eyelid and encroached upon the left ala of the nose. About the malar prominence was an elevated bluish spot as large as a pea. The left nostril was considerably flattened, about one-half normal. Two-thirds of the cheek showed involvement in a tumor mass that hung down over the under lip within one-quarter inch of the margin of the lower jaw. The tumor mass was of a dark blue discoloration and was convoluted. Upon stooping, this mass would increase in size very perceptibly. The swelling was soft, the skin covering it appearing very thin to the touch. Upon pressure it could readily be made smaller by forcing the blood out of it. The evidence that there were cavities filled with fluid was unmistakable to the touch. The protrusion of the tumor was such that it was on a level with a line drawn from the tip of the nose across the cheek and down to the chin. The lower lip and the chin showed atrophic changes corresponding to the shape and contour of the tumor, caused by pressure of the overhanging mass. The incisor and canine teeth of the upper jaw had long been destroyed by the constant attrition of the tumor. Within the mouth there could be seen large bluish masses of mucous membrane lying between the molar teeth and filling about one-third of the cavity of the mouth, caus-

Fig. 26.—Miss S. Appearance of patient shown in Fig. 25, December 1, 1906. A slight scarring of upper lip occurred, the result of a superficial slough. The scar was excised a year later.

ing an impediment of speech. Fear of biting this mass during mastication and causing free bleeding was a constant source of danger. It was a great discomfort to the patient because of the difficulty in eating. The patient carried the tumor in a sling partly because it relieved the weight and partly because it hid from view the unsightly mass.

Having had no previous experience with the hot-water injection, I spoke very discouragingly to her because I did not know how much good or how much harm I might be able to do her should I undertake to interest myself in her behalf. She had consulted a number of physicians, good and bad, during the past six years, seeking relief, but invariably returned home downhearted and discouraged.

The idea that occurred to me at first was to reduce the pendulous part of the tumor with the procedure that incurred the least amount of risk. I thought this to be the ligation method—strangulation by introducing loops of silk subcutaneously along the mucocutaneous margin of the lip. With a very small cambric needle I ligated the lower third of the tumor. Small as the punctures were, the bleeding was most obstinate, continuing for sixteen hours. With the aid of ice and pressure it was checked. The experiment demonstrated that it was not the procedure to be followed. The threads became infected and were removed on the

fifth day. After nine days the infection had subsided. The condition remained the same, excepting that about one-half inch of the lip on the right of the median line had contracted; furthermore, hard nodules could be felt throughout the portion that had been ligated.

The condition as it presented itself after two weeks gave me considerable encouragement, and I concluded to resort to the treatment of injecting boiling water. The risks seemed to increase while I was debating with myself as to the advisability of using this method, and I spoke very frankly to the patient of what might happen. This case seemed to me to be one particularly prone to risks, inasmuch as so much mucous membrane had to be dealt with. To inject boiling water into spaces filled with blood seemed to me an operation not free from danger.

The first injection, under aseptic precautions, was made on June 25, 1906. Under ether narcosis, four ounces of boiling water were injected into the tumor. A small aspirating needle, three inches in length, was inserted into the swelling through healthy skin on the right cheek, about one-eighth of an inch distant from the tumor margin and about one-half inch below the nose. In making these injections, the advice of Dr. Wyeth was closely followed. All of the tumor was injected excepting the portion on the inside of the cheek. About ten minutes were required to inject the

four ounces of boiling water. Time was lost by not having been able to obtain a Wyeth syringe. An ordinary glass syringe holding two ounces was used, the aspirating needle being attached to the syringe with rubber tubing. It was a clumsy way of doing this work, but it answered the purpose satisfactorily. The handling of boiling water is a rather delicate task.

While the injection was being made, the patient's face was protected in the immediate vicinity of the needle so that the boiling water which was being forced out at the needle junction by the confined steam would not scald the skin. The hands of the operator were protected by a folded towel. It did not serve the purpose well, and to those who have occasion to handle boiling water I would suggest the use of heavy duck gloves.

To anticipate as far as possible any danger from embolism, peripheral compression was made. In introducing the needle, it was carried through the mass till the point could be distinctly felt through the skin. The withdrawing of the needle about one-half inch gave a reasonable amount of assurance that the boiling water could be forced gently into the affected area with little danger of provoking sloughing. The needle was introduced in four different places at various angles. In some places the integument turned pale, in others an ashen gray, while the water was being injected into the tumor. The

heat of the water could be very distinctly felt through the tissues—they were hot.

After the operation the patient was put to bed. The following day the left side of the face was very much swollen, but not painful. The left eye was partially closed. A large blister had formed along the mucous border of the lip. The tumor felt hard to the touch. There was a slight rise in temperature (99.6°). Two days later the temperature returned to normal. The patient left the hospital on the fifth day. On July 26 a large scab which had formed on the lip margin was removed. The whole tumor was hard, excepting about two-thirds of the tumor mass inside of the cheek. Diminution by granular metamorphosis had reduced the tumor to one-half its original size. I wish to state here that a linear sloughing of the skin occurred which extended from the ala of the left nostril to the margin of the lip. It resulted in a cicatrix that was but slightly disfiguring. This scar was removed subsequently.

On August 2, under ether anesthesia, the buccal mucous membrane was injected with three ounces of boiling water. The outcome was most favorable, only a small slough resulting.

On August 18, under ether anesthesia, two ounces of hot water were injected into the lip. Some difficulty was encountered in introducing the needle on account of the hardened condition of the tissues.

On August 30, without anesthesia, one ounce of boiling water was injected into the buccal mass.

On September 15 conditions began to take on a normal appearance.

On September 25, without anesthesia, one ounce of boiling water was injected into the outer portion of the lip, which still appeared quite large. Ten days later the lip was almost normal.

On October 8 an injection of one ounce of alcohol* caused the lip to assume so nearly a normal condition that further intervention was deemed unnecessary and the patient was discharged.

*In substituting alcohol for boiling water, I wish to state that I feared too much contraction might take place with the use of boiling water and cause a deformity of the lip. In this assumption a more extensive experience now convinces me that I was in error. The alcohol injection was not necessary, and did not influence the condition. It was the time given metamorphosis that brought about the result.

INDEX

A

Advisability of giving an anesthetic, 51
Aneurysm, cirsoid, 52
Angioma, nevus complicating, 41
  time required to disappear after an injection, 50
Angiomata, behavior of, after injection of hot water, 50, 51
  capillary, 29
  cavernous, 18
  classification of, 17
  location of, 19
  pain in connection with, 19
  of the tongue, dangers of injecting, 35
  plexiform, clinical characteristics of, 28
  theory of, 17
  various methods other than surgical used to destroy, 32
Arrangement of operating room, 45

B

Bärensprung's view, 29
Behavior of an angioma after hot-water injection, 50, 51
Boiling water used in conjunction with Paquelin cautery, 41
Boiling water, Wyeth method of injecting, 32

C

Capillary form of angioma, 29
Care in injecting an angioma of the lip, 35
Care in injecting tip of the nose, 49
Characteristics of cavernous angiomata, 18
Characteristics of plexiform angiomata, 19
Cicatricial tissue, a serious obstacle to the injection of hot water, 59
Cirsoid aneurysm, 52
Classification of angiomata, 17
Clinical characteristics of a cavernous angioma, 18
Cork-protected needle, 45

D

Danger of injecting angioma on the tongue, 35
Dangers of injecting boiling water into an angioma, 36

E

Edema of adjacent tissues following injection, 50

F

Face, protection of, 45
Force used in injecting hot water, 45-48

H

Hands, protection of, while making injection, 43

I

Injection of boiling water, dangers of, 36
  syringe for, 41
  technic for, 41
  Wyeth method, 32
Injection of hot water, edema of adjacent tissues following, 50
  force used in, 45-48
  quantity to be used at one time, 49
  time consumed in making the, 49
Injections of hot water, subsequent, when indicated, 49
Introduction of the needle and force used in injecting hot water, 45-48

J

Jacketed syringe, 43

L

Lip, care in injecting angioma on the, 35
Location of angiomata, 19
Larry's theory, 30

N

Needle, cork-protected, 45
  introduction of, 45-48
  size and character of, 43
Nevus complicating an angioma, 41
Nose, care in injecting tip of the, 49

O

Operating room, arrangement of, 45

P

Pain in connection with angiomata, 19
Paquelin cautery, boiling water used in conjunction with, 41
Plexiform angiomata, clinical characteristics of, 28
Protection of hands while making injection, 43
Protection of patient's face, 45

Q

Quantity of hot water to be injected at one time, 49

R

Ribbert on the genesis of angiomata, 30

S

Salient points to be considered in the treatment of angiomata, 31
Simon's theory, 30
Size and character of needle, 43
Strangl's argument, 30
Subsequent injections, when indicated, 49
Syringe for injecting boiling water, 41
Syringe, jacketed, 43

T

Technic of injecting boiling water, 41
Theory of angiomata, 17
Time consumed in making injection, 49
Time required for an angioma to disappear after injection, 51
Tongue, danger of injecting an angioma of the, 35

V

Various methods other than surgical used to destroy an angioma, 32
Virchow's theory of the origin of angiomata, 30

W

Wyeth method of injecting boiling water, 32

114511

LANE

MEDICAL LIBRARY

Gift
San Francisco County Medical
Society